

# Ruptured spontaneous heterotopic pregnancy with hemoperitoneum: a case report

Gravidez heterotópica rota espontânea apresentando hemoperitônio: relato de caso

Caroline Petersen da Costa Ferreira<sup>1</sup>, Henrique Cunha Mateus<sup>1</sup>, Augusto Canton Gonçalves<sup>1</sup>, Rodrigo Jaqueto Nomura<sup>1</sup>, Bruna Nascimento Cruzillard<sup>1</sup>, Bruno Henrique Nunes Hirata<sup>2</sup>, José Cesar Assef<sup>3</sup>

## Abstract

**Introduction:** Heterotopic pregnancy (HP) is the coexistence of intrauterine (IU) and extrauterine (EU) gestation. It is a rare and potentially fatal condition if not correctly treated or diagnosed. **Case Report:** We present a 33-year-old woman with a 16-week topical pregnancy with spontaneous rupture of an ectopic pregnancy (EP) in the uterine tube. At first, the patient had diffuse abdominal pain, specifically in the lower abdominal level and tachycardia. The evaluation of the fetus showed no signs of distress. Abdominal and transvaginal ultrasound (US) showed free intraperitoneal fluid, a normal aspect IU gestation with a positive fetal heart rate, consistent with a fetal age of approximately 16 weeks, signs of parenchymal vascular hypoflux of the spleen on the color Doppler study, associated with a splenic vein with low vascular amplitude flow. General surgery team was requested and in order to rule out aneurysm of splenic vessels as a source of bleeding, she had an abdominal angiogram that showed a moderate amount of free fluid, ectasia of gonadal and uterine vessels, with no signals of active bleeding and no spleen changes. No signs of EP were identified in the exam. The patient presented hemodynamic deterioration with maintenance of abdominal girth. An emergency exploratory laparotomy was performed under general anesthesia through a supra and infraumbilical incision, leading to a finding of a ruptured EP. There was a 3-cm right tubal ruptured ectopic pregnancy. A total right salpingectomy was performed with removal of the hemoperitoneum and peritoneal lavage. The patient recovered uneventfully and was discharged from the hospital within

5 days. **Conclusion:** Heterotopic pregnancy should be kept in mind even if an intrauterine pregnancy is diagnosed.

**Keywords:** Heterotopic pregnancy, Hemoperitoneum/surgery

## Resumo

**Introdução:** A gravidez heterotópica (HP) é a coexistência da gestação intrauterina (IU) e extrauterina (EU). É uma condição rara e potencialmente fatal se não tratada ou diagnosticada corretamente. **Relatamos uma emergência cirúrgica** numa gestante de 33 anos com uma gravidez tópica de 16 semanas e ruptura espontânea de uma gravidez ectópica (GEC) na tuba uterina, submetida a cirurgia e ressecção da tuba sem complicações de gravidez uterina.

**Relato de Caso:** Uma mulher de 33 anos, G3P2, com 16 semanas de gestação, foi ao serviço de emergência obstétrica (SEO) devido a dores abdominais por uma semana. No início, a paciente tinha dor abdominal difusa, especificamente no abdome inferior e taquicardia. A avaliação do feto não mostrou sinais de sofrimento. Foi realizado um ultrassom abdominal e transvaginal (USA), que demonstrou líquido livre e uma gestação IU de aparência normal, com uma frequência cardíaca fetal positiva, consistente com uma idade fetal de aproximadamente 16 semanas, um baço com dimensões, morfologia e ecotextura habituais, com sinais de hipofluxo vascular no estudo doppler, associado a uma veia esplênica com baixa amplitude do fluxo vascular. Uma vez que paciente se encontrava hemodinamicamente estável, foi optado pela realização de angiotomografia abdominal para descartar aneurisma roto de artéria esplênica como fonte de sangramento. Considerando a gravidade da anemia, ela recebeu 02 unidades de hemoconcentrado. A tomografia mostrou piora da quantidade moderada de líquido livre, ectasia de vasos gonadais e uterinos, sem sinais de sangramento ativo e sem alterações no baço. Não foram identificados sinais de gestação IU neste exame. O paciente apresentou alteração hemodinâmica e manteve dor abdominal. Foi realizada uma laparotomia exploradora de emergência sob anestesia geral através de uma incisão supra e infraumbilical, evidenciando 2 L de sangue na cavidade e GEC rota na tuba a direita com

1. Santa Casa de São Paulo School of Medical Sciences. Department of Surgery. São Paulo – SP – Brazil

2. Santa Casa de São Paulo School of Medical Sciences. School of Medicine. São Paulo – SP – Brazil

3. Santa Casa de São Paulo School of Medical Sciences. Department of Surgery. São Paulo – SP – Brazil

**Institution:** Santa Casa de São Paulo School of Medical Sciences. Department of Surgery São Paulo – SP – Brazil

**Correspondence Address:** Bruno Henrique Nunes Hirata. Rua Marquês de Itu, 836 – 01223-001 - São Paulo - SP – Brasil

cerca de 3 cm de extensão. Foi realizada uma salpingectomia direita com a remoção do hemoperitônio e lavagem da cavidade. A paciente se recuperou sem intercorrências e teve alta do hospital em 5 dias. **Conclusão:** A gravidez heterotópica deve ser mantida em mente, mesmo se uma gravidez intrauterina for diagnosticada.

**Palavras chave:** Gravidez heterotópica, Hemoperitônio/cirurgia

## Introduction

Heterotopic pregnancy (HP) is the coexistence of intrauterine (IU) and extrauterine (EU) gestation. It is a rare occurrence<sup>(1)</sup>. EU usually occurs in Fallopian tube and uncommonly in cervix or ovary<sup>(2)</sup>.

Due to several factors, including increasing use of assisted reproductive techniques and higher incidence of pelvic inflammatory disease, there has been a significant increase in occurrence of HP over the last decades<sup>(2)</sup>.

It is a rare and potentially fatal condition if not correctly treated or diagnosed. In this case report, we present a 33-year-old woman with a 16-week topical pregnancy with spontaneous rupture of an ectopic pregnancy (EP) in the uterine tube. The patient was submitted to surgery and uterine tube resection without uterine pregnancy complications.

## Case report

This study was sent to the Ethics Committee - Santa Casa de Misericórdia de São Paulo, CAAE: 45318721.2.0000.5479 and approved under the number 4.648.356.

A 33-year-old woman at 16 weeks' gestation went to the obstetric emergency service (ES) due to abdominal pain for one week. The patient had got two previous pregnancies, both with vaginal delivery. One of the babies had died 24 hours after delivery due to unknown reasons, and the other one had a normal evolution. Prior to this gestation, the patient had treated multiple urinary tract infections, but with no history risk factors for EP.

The patient had been receiving Cephalexin for 1 week to treat a urinary tract infection. At first, the patient had diffused abdominal pain, specifically in the lower abdominal level and tachycardia. The evaluation of the fetus showed no signs of distress. Admission laboratory workup is summarized in Table 1.

An abdominal and transvaginal ultrasound (US) was performed, which demonstrated free intraperitoneal fluid and a normal aspect IU gestation with a positive fetal heart rate consistent with a fetal age of approximately 16 weeks. The abdominal US showed a

Table 1

Laboratory exams	
Hemoglobin:	6g/dL
Leukocytosis:	232.000 /uL

spleen with usual dimensions, morphology and echotexture with signs of probable parenchymal vascular hypoflux on the color Doppler study, associated with a splenic vein with low vascular amplitude flow. To rule out aneurysm of splenic vessels as a source of bleeding, an abdominal angiotomography and general surgery team were requested.

Considering the severity of the anemia, she received 2 units of blood packs. The CT-scan showed a moderate amount of free fluid, ectasia of gonadal and uterine vessels, with no signals of active bleeding and no spleen changes. No signs of EP were identified in the exam.

The patient had hemodynamic deterioration with maintenance of abdominal girth. An emergency exploratory laparotomy was performed under general anesthesia (figures 1, 2, 3).

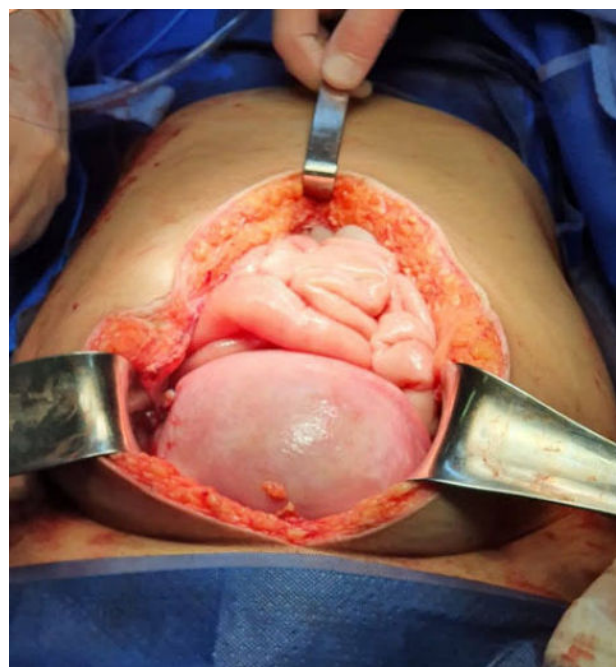
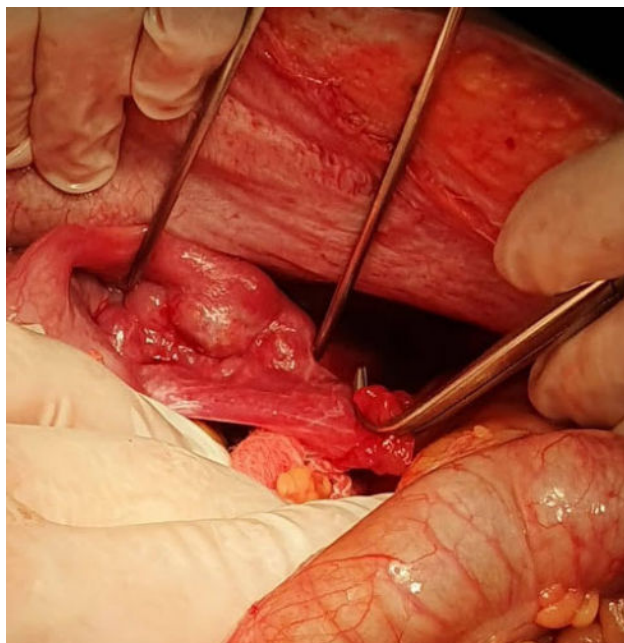


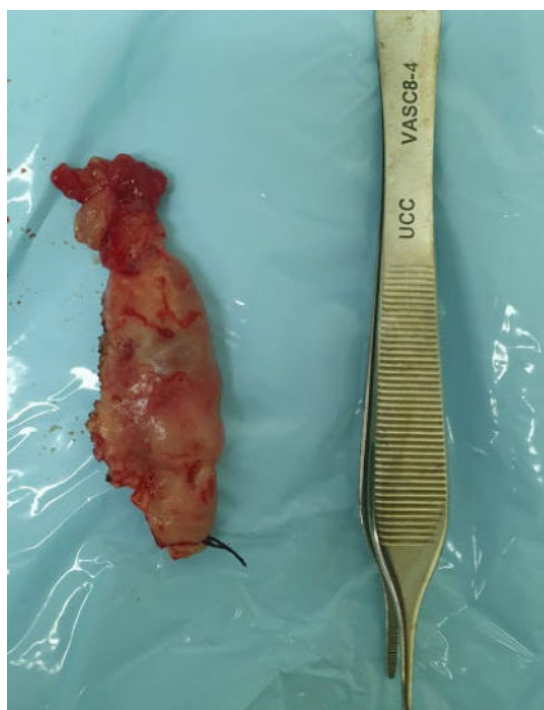Figure 1 - Enlarged utero compatible with 16-week gestation.

## Discussion

HP is the simultaneous occurrence of two (or more) implantation sites. It is primarily manifested as concomitant IU and EU pregnancies<sup>(3)</sup>. HP is rare, but there has been a significant increase in incidence over the last decades, with widespread use of assisted reproductive techniques. The incidence of HP is estima-



**Figure 2 -** Right tubal ruptured ectopic pregnancy



**Figure 3 -** Salpingectomy specimen

ted to be 1 in 30,000 in spontaneous pregnancies, but in pregnancies conceived using assisted reproductive techniques, it is reported to be as high as 1 in 100<sup>(4)</sup>.

The risk of a HP increases if the patient has some of these pathologies: previous ectopic pregnancy, cigarette smoking, tubal pathologies such as pelvic inflammatory disease, tube-ovarian abscess, previous tubal/pelvic surgery and the most impact in these cases is assisted pregnancy, according to Gupta et al<sup>(5)</sup> our

patient presented in this case report had no heterotopic pregnancy risk factors.

The clinical manifestations of HP are uncharacteristic; the most common symptom is the abdominal pain that can simulate a lot of misdiagnosis as acute appendicitis and an abortion. Vaginal bleeding could be associated. When rupture of the uterine tube occurs, the patient may present signs and symptoms of hypovolemic shock such as hypotension, tachycardia, skin paleness and altered level of consciousness<sup>(6)</sup>. Our patient presented abdominal pain and tachycardia with no other symptom.

The diagnosis of HP is challenging due to concern about the effects of radiation coupled with anatomical and functional changes during pregnancy. HP is usually diagnosed between the 5<sup>th</sup> and the 34<sup>th</sup> weeks of gestation. According to Sturlese et al<sup>(6)</sup>, 70% of HP were diagnosed between weeks 5 and 8 of gestation, 20% between 9 and 10, and 10% after week 11<sup>(6)</sup>.

The high resolution transvaginal ultrasound is the most used and important diagnostic tool; the sensitivity and specificity in ectopic pregnancy diagnosis is 71-100% and 41-99%, respectively<sup>(4)</sup>. In our case, the transvaginal US and abdominal US show no signs of EP but showed an important amount of free abdominal fluid.

The magnetic resonance is a promise as a new modality. However, it is not practical for routine use in emergency service<sup>(7)</sup>. Thus, we suggested the diagnostic hypothesis of splenic artery aneurysm and to perform the preoperative diagnosis we opted, together with the gynecology department, to perform an abdominal angiotomography. The CT-scan showed a moderate hematic fluid in the abdominal cavity and pelvic vessels ectasia and no signs of ectopic gestation. According to Barrenetxea et al<sup>(8)</sup>, in literature review between 1994 and 2004 only 21 out of 80 cases were diagnosed preoperatively<sup>(8)</sup>.

The options in treatment for HP are separated in two options: clinical or surgical approach. Clinical option is performed with medical treatment, the drug options are potassium chloride or hyperosmolar glucose that can be injected locally into the intact ectopic/heterotopic gestational sac or fetus via laparoscopy or transvaginal sonography. Drugs such as methotrexate, RU486 and prostaglandins cannot be used because of the risks of a topic gestation<sup>(9-10)</sup>.

The surgical option is salpingostomy or salpingectomy by laparoscopy or laparotomy, depending on the condition of the patient. In our case, we did not have a previous diagnosis of heterotopic pregnancy and exploratory laparotomy was indicated due to acute hemorrhagic abdomen. The main principle during surgery (be it elective or urgent as in our case) is the preservation of the intrauterine pregnancy with

minimal manipulation of the uterus. Intrauterine pregnancy is expected to develop normally<sup>(10)</sup>.

## Conclusion

Heterotopic pregnancy should be kept in mind even if an intrauterine pregnancy is diagnosed.

---

## Authors' Contributions

**Caroline Petersen da Costa Ferreira:** Data Collection, Conceptualization, Resource Management, Project Management, Investigation, Methodology, Writing - Original Preparation, Writing - Review and Editing, Supervision, Validation, Visualization.

**Henrique Cunha Mateus:** Data Collection, Conceptualization, Supervision, Validation, Visualization.

**Augusto Canton Gonçalves:** Validation, Visualization.

**Rodrigo Jaqueto Nomura:** Validation, Visualization.

**Bruna Nascimento Crouzillard:** Validation, Visualization.

**Bruno Henrique Nunes Hirata:** Writing - Original Preparation, Writing - Review and Editing.

**José Cesar Assef:** Supervision, Validation, Visualization.

**Conflict of interests:** There were no conflicts of interest for the present study

---

## References

1. Karkee R, Sharma A, Dangal B. Heterotopic pregnancy: a challenge in early diagnosis. *J Nepal Health Res Counc*. 2019;17(3):413-5.
2. Skrajna A, Cendrowski K, Alkhalayla H, Sawicki W. Heterotopic pregnancy. A case report. *J Ultrason*. 2012;12(50):342-8.
3. Mihmanli V, Kilickaya A, Cetinkaya N, Karahisar G, Uctas H. Spontaneous heterotopic pregnancy presenting with hemoperitoneum. *J Emerg Med*. 2016; 50(1):44-6.
4. Schroepel TJ, Kothari SN. Heterotopic pregnancy: a rare cause of hemoperitoneum and the acute abdomen. *Arch Gynecol Obstet*. 2006; 274(3):138-40.
5. Gupta A, Gupta A, Gupta B, Mahajan N, Vi A, Chadda A. Heterotopic pregnancy: a case report. *Int J Reprod Contracept Obstet Gynecol*. 2017; 6(5):2121-3.
6. Sturlese E, Retto G, Palmara V, Tripodi A, Tripodi M, Sorace M, et al. Heterotopic pregnancy: case report. *Clin Exp Obstet Gynecol*. 2010; 37(1):69-72.
7. Tan PL, Ridley LJ. Incidental heterotopic pregnancy demonstrated on magnetic resonance imaging. *Australas Radiol*. 2005; 49(1):75-8.
8. Barrenetxea G, Barinaga-Rementería L, Lopez de Larruzeta A, Agirreagoikoa JA, Mandiola M, Carbonero K. Heterotopic pregnancy: two cases and a comparative review. *Fertil Steril*. 2007; 87(2):417.e9-15.
9. Fernandez H, Lelaidier C, Doumerc S, Fournet P, Olivenne SF, Frydman R. Nonsurgical treatment of heterotopic pregnancy: a report of six cases. *Fertil Steril* 1993; 60(3):428-32.
10. Ocal P, Erkan S, Cepni I, Idil MH. Transvaginal ultrasound-guided aspiration and instillation of hyperosmolar glucose for treatment of unruptured tubal ectopic pregnancy. *Arch Obstet Gynecol*. 2007; 276(3):281-3.

---

Article received: 27 October 2021

Article approved: 14 May 2022

Article published: 19 May 2022

**Responsible Editor:** Prof. Dr. Eitan Naaman Berezin (Editor-in-Chief)